

Heterotopic Ossification

INTRODUCTION

Heterotopic ossification (HO) is the development of bone in abnormal areas, usually in soft tissues. Heterotopic ossification develops most commonly in individuals who have an injury, such as spinal cord injury, that results in neurologic deficits. It is therefore referred to as **neurogenic heterotopic ossification**.

CLASSIFICATION

Samuel L. Stover, M.D. developed a classification that differentiates between myositis ossificans and heterotopic ossification. The four types of soft tissue ossification are:

- 1- myositis ossificans progressiva which occurs in childhood and progresses until death (often in the early 20's);
- 2- myositis ossificans traumatica which follows injury to muscle tissue;
- 3- myositis ossificans non-traumatica which has an unknown etiology and
- 4- neurogenic heterotopic ossification.

CAUSE / ETIOLOGY

No one is quite sure what causes heterotopic bone formation. Many reports propose it is related to a type of mesenchymal metaplasia, meaning that connective tissue cells change their characteristics into bone forming cells. It is not known why the cells change function but it is thought to be some type of inflammatory reaction.

In individuals with spinal cord injury, heterotopic ossification will usually begin forming in the intramuscular connective tissue within four months of the injury. When the reaction begins, there will be a deposition of calcium phosphate in the intramuscular tissue. However, ossification occurs only when the calcified material goes on to form

hydroxyapatite crystals. Once bone formation has occurred, it rarely disappears spontaneously.

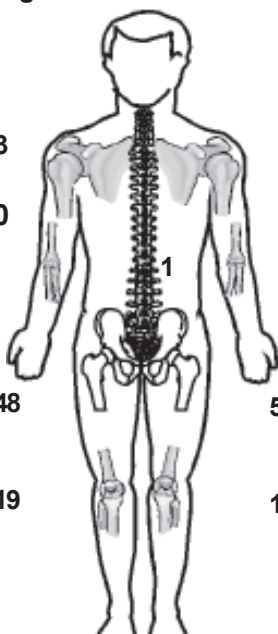
INCIDENCE AND LOCATION

The incidence rate of heterotopic ossification in individuals with spinal cord injury is approximately 16 to 53 percent. It will always occur **below** the level of injury.

Heterotopic ossification may occur anywhere in the body but is most frequently found around the joints or long bones. HO is most commonly found around the hips, followed by the knees, shoulders and elbows and sometimes in the paravertebral area. It has also been reported to occur at the ankles and at the base of pressure sores. In the hips it is most common in the flexor or adductor areas. In the knees it occurs along the medial-collateral ligament. Heterotopic

Location & Incidence of HO

Right	Left	Joints Involved	
3	5	Shoulders	8
0	1	Elbows	1
		Paravertebral	1
48	50	Hips	98
19	15	Knees	34



Location and incidence of HO found in 77 patients by prospective x-ray survey of 250 SCI patients. Some patients had multiple joint involvement.[3]

ossification in the shoulders is usually mild and does not cause much clinical difficulty with function.

DIAGNOSIS

If only a small amount of bone is forming there may not be any clinical signs or symptoms. If it is a large formation, the patient may experience all the symptoms of an inflammatory process. When heterotopic ossification occurs around the hip, there is usually swelling of the leg (most pronounced around the hip area). There may be redness, heat in the leg, and the patient may have a low grade fever. The physician will then have to differentiate between other problems which can cause leg swelling, particularly thrombophlebitis, deep venous thrombosis, cellulitis, joint sepsis, hematoma, fracture and trauma. Most can be easily distinguished on a clinical basis or by routine x-ray, however a venogram and bone scan are needed to differentiate between deep venous thrombosis and early heterotopic ossification.

A negative venogram will generally rule out deep venous thrombosis, but does not automatically confirm a diagnosis of heterotopic ossification. Conversely, a negative bone scan will rule out heterotopic ossification, but does not give a conclusive diagnosis of deep venous thrombosis. Both tests are required because deep venous thrombosis and heterotopic ossification may occur in the same patient in the same extremity; therefore having one condition does not preclude the other condition.

In addition, the bone scan will show heterotopic ossification seven to ten days earlier than an x-ray. The three-phase bone scan is perhaps the earliest method of detecting heterotopic bone formation. However, in some cases, an abnormality may be detected in the early phase which does not necessarily mean it will go on to form heterotopic bone. Another finding, often misinterpreted as early heterotopic bone formation, is an increased (early) uptake around the knees or the ankles in an early spinal cord injured patient. It is not clear

exactly what this means because these patients do not develop heterotopic bone formation. It has been hypothesized that this may be related to the autonomic nervous system and its control over circulation.

When heterotopic bone forms a year or more after spinal cord injury, it is usually caused by some other predisposing factors. It is most frequently the result of infection, either localized or generalized. If a septic hip develops, heterotopic bone often forms around the joint. A severe systemic illness occasionally will cause this type of reaction. Also, surgery to the area or a more distant area may induce late onset heterotopic ossification. The hip is particularly susceptible in these cases.

PREVENTION AND TREATMENT

Preventing heterotopic ossification should be the primary focus of treatment. Resulting complications of severely decreased range of motion and contractures can interfere with an individual's mobility and self-care. This can cause problems with sitting and activities of daily living.

Once HO forms, surgery is the only viable option. Anti-inflammatory agents, calcitonin, diathermy, and ultrasound have not been effective in treating heterotopic ossification once it is formed. Evidence supporting radiation therapy as an effective method of preventing heterotopic ossification is increasing. It seems to be particularly helpful for patients who have had total hip replacement surgery. Patients receiving radiation therapy during the first week to ten days following surgery appear to have less heterotopic bone formation than those who do not, but more research is needed in this area.

Because of the pain associated with myositis ossificans traumatica, some feel the initial treatment should call for bedrest. However, with loss of sensation in spinal cord injury patients, a reasonably aggressive passive exercise program to maintain range of motion should be continued.

Certain antiinflammatory agents, such as

indomethacin, ibuprofen and aspirin, have shown some effect in preventing reoccurrence of heterotopic ossification after total hip replacement. Although not evaluated in persons with spinal cord injury, these agents may also have some value in preventing the initial formation. The drug etidronate disodium (Didronel) was one of the first therapeutic agents that seems to have a definite effect on preventing heterotopic bone. A multi-center, double-blind, placebo controlled study was conducted with 181 participants. Treatments were given 21 and 120 days after injury for 12 weeks. For two weeks a dosage of 20mg per kilogram per day was given and this was followed by ten weeks of 10mg per kilogram per day.

By the end of the twelve weeks, those in the placebo group showed much more bone formation than the patients in the drug treated group. At nine months after ending treatment, both groups still had some increase in heterotopic bone formation, but the treatment group never developed as severe heterotopic ossification as the placebo group. Overall, the treatment does not affect the incidence of bone formation, but the severity of heterotopic ossification appears to be less for those patients receiving etidronate disodium. The drug does not prevent the inflammatory reaction but it does help prevent ossification during the initial few months when heterotopic bone formation is most likely. Thus, the predisposition for ossification is decreased.

Should the patient develop an inflammatory reaction or show definite signs of recurrence during the twelve weeks of prophylactic treatment, medication should be continued for six months to a year if a large amount of heterotopic bone is forming.

The most common side effects of the drug are nausea and occasional vomiting. About 15 to 20 percent of patients will suffer from these problems, which are often relieved by dividing the dosage in half and administering the medication twice daily. The medication should also be given when the patient has an empty stomach.

Symptoms are fully relieved once the drug is discontinued. Most patients will also develop hyperphosphatemia, because the drug increases the serum phosphate level. This also returns to normal once the drug is discontinued. Another possible complication may be osteomalacia. If the etidronate disodium is given for six months or more, osteomalacia may develop. However, there is no evidence when the drug is continued for a prolonged period.

More recently, initial intravenous etidronate disodium has been advocated. Antiinflammatory agents and radiation therapy may actually prevent the inflammatory reaction and matrix formation, whereas disodium etidronate prevents the ossification of the matrix.

If ossification continues during treatment, the most likely answer may be lack of drug compliance. First determine whether the patient is actually taking the medication and then make sure the drug is being absorbed. Checking the serum phosphate level will give a good indication as to whether the etidronate disodium is being absorbed. If the serum phosphorus level had not increased, it may mean the drug is not being absorbed.

SURGICAL INTERVENTION

When surgery is indicated to remove heterotopic ossification, first eliminate all signs of infection in the patient. Any pressure ulcers or skin lesions should be completely healed before undertaking surgery. Also, a urine culture and sensitivity should be done two weeks before surgery. A sterile urine should be obtained before surgery, because the literature suggests that an infected bladder may lead to an infection in the hip. In addition these patients should be placed on prophylactic antibiotics which should be continued postoperatively.

No matter which joint is operated on, during surgery remove enough bone with a wedge resection so that functional range of motion will be achieved. Attend to hemostasis during surgery and

use suction drainage postoperatively. During recovery, start graduated range of motion exercise very slowly. In patients injured for several years, there will be severe osteoporosis of the bone from disuse, so extreme care is necessary during surgery and postoperatively to prevent fractures.

After surgery, careful observation is warranted for recurrence of the heterotopic bone, infection, and hemorrhage. Many times the recurrence of heterotopic bone may be avoided if surgery is deferred until the bone is mature; however, the problem is in assessing whether the bone is mature. X-rays and biopsies do not give an accurate determination of maturity. It is also very difficult to get an accurate maturity reading from a bone scan because each scan must be replicated at the same point of bone in order to quantify whether the bone is in a plateau phase. In addition, there is some indication that even when the bone is shown to have a plateau uptake of radionuclide on the bone scan, sometimes this bone has variable turnover rates and what was thought to be a plateau phase becomes active several months later.

To minimize recurrence of heterotopic bone after surgery, etidronate disodium is given 20mg per kilogram per day for two weeks prior to surgery and 10mg per kilogram per day postoperatively. However, some patients, particularly those with total hip replacement, must be maintained on 20mg per kilogram per day postoperatively because the lower dosage will not be enough to prevent recurrence. In addition, because of the risks and frequency of postoperative recurrence, radiation therapy and indomethacin should also be given as recommended in the total hip replacement literature. It is suggested that the patient be kept at rest for the

first week post surgery, then begin passive range of motion exercises as part of physical therapy.

CONCLUSION

In conclusion, more information is needed about the basic pathophysiology of heterotopic ossification, its causes, prevention and treatment. Until more is known, continuing range of motion exercises and treatment with etidronate disodium and antiinflammatory agents seems to be the best course of prevention. These measures minimize development of heterotopic bone in newly injured spinal cord patients and also postoperatively in individuals with SCI.

REFERENCES

- [1] Banovac K, Gonzalez PA, Renfree, KJ. Treatment of heterotopic ossification after spinal cord injury. **J Spinal Cord Med** 1997;20:60-65.
- [2] Maynard F, Karunas, R et al. Management of the neuromusculoskeletal systems. In: Stover SL, DeLisa, JA, and Whiteneck, GG, eds, **Spinal cord injury: clinical outcomes of the model systems**. Frederick, Md: Aspen Publishers, 1985:160-163.
- [3] Stover SL. Heterotopic ossification following spinal cord injury. In: Bloch RF, Basbaum M, eds, **Management of spinal cord injuries**. Baltimore: Williams and Wilkins, 1986: 284-301.
- [4] Stover SL (presenter), Hall BA (producer). **Heterotopic Ossification in Spinal Cord Injury**[video] Birmingham, AL: UAB Dept of PM&R, 1987. (Available from UAB RRTC in SCI, 1717 6th Ave S, Birmingham, AL 35233).

Published by:

Office of Research Service
619 19th Street South - SRC 529
Birmingham, AL 35249-7330
(205) 934-3283 or (205) 934-4642 (TTD only)
Please check out our website at www.spinalcord.uab.edu

This publication is supported by grant #H133N060021 from the National Institute of Disability and Rehabilitation Research, Office of Special Education and Rehabilitative Services, U.S. Department of Education, Washington, DC. Opinions expressed in this document are not necessarily those of the granting agency.

Review Date: March, 2009
Reviewed By: C.T. Huang, MD
Developed by: Samuel L Stover, MD (1997)
Edited by: Linda Lindsey, MEd, Media Specialist (1997)

© 2009 Board of Trustees of the University of Alabama. The University of Alabama at Birmingham provides equal opportunity in education and employment.

UAB PHYSICAL MEDICINE
AND REHABILITATION
SPAIN REHABILITATION CENTER